

I'VE GOT YOU UNDER MY SKIN – THE MOULDS OF MAN

There are thought to be over 1.5 million species of fungi. Of these, most live on decaying vegetation, in partnership with algae (lichens) or tree roots (mycorrhizas) or are parasites of plants or insects. Only a few tens of species cause us any direct harm but *Mycologist* is featuring a series of articles about the main species that do cause irritating, and in some cases life-threatening human infections. In this issue, dermatophytes are discussed.

Dermatophytes – the skin eaters

LIZ JOHNSON

Mycology Reference Laboratory, Health Protection Agency Southwest, Myrtle Road, Kingsdown, Bristol BS2 8EL

One indication that a disease is prevalent in the general population is when it appears in literary offerings, is depicted in paintings by the old masters, and when it is given a colloquial name that bears no resemblance to the causative organism. Dermatophyte or ringworm infections have achieved this notoriety with the ignominious epithets of 'athlete's foot' and 'jock itch' being applied to infection of various body parts. Although not life-threatening, superficial mycoses due to dermatophyte fungi have been amongst the most common communicable diseases in the population since antiquity and have considerable social and health-economic implications.

Dermatophyte infections have a worldwide distribution with geographical differences in the incidence and prevalence of different dermatophyte species. They can be divided into species that are anthropophilic spreading by direct or indirect contact with an infected human host, zoophilic, or geophilic. Infections due to zoophilic dermatophytes, most often seen on exposed body sites, are acquired from animals as diverse as rodents, pigs, chickens, cattle, horses, cats, dogs, monkeys and hedgehogs. Those dermatophyte fungi that are parasitic on man and animals are derived from free-living geophilic soil fungi but have evolved to obtain their keratin before it is shed and have thus adopted a parasitic mode of life. The ancestral keratinophilic soil fungi provide an invaluable service in the primary decomposition of shed hairs, feathers, horns, hooves, nails and keratinized portions of animal corpses thus moving valuable nutrients along the cycle of life (Fig 1). Often the species that are isolated primarily from animals cause the strongest reddening and inflammation when they cause ringworm on humans.

Dermatophytes can be isolated from the environment by hair baiting techniques and sexual forms of these fungi belonging to the genus *Arthroderma*, (phylum Ascomycota) have often been identified. Evolution from geophilic to zoophilic or anthropophilic forms appears with few exceptions to have been associated with a loss of the ability to reproduce sexually.

Owing to their lack of sexual reproduction the pathogenic ringworm fungi are classified as Deuteromycota or Fungi Imperfecti and can be divided into three genera *Epidermophyton*, *Trichophyton* and *Microsporum* based on their morphological characteristics. Different genera and species within those genera differ in their ability to produce asexual macroconidia (large, multi-septate) and microconidia (small, unicellular aleuriospores). There are numerous differences in both microscopic and colonial appearance that help in the identification of the different dermatophyte species but it is the microscopic features that have assumed the greatest significance in




Fig 1 'Mumified' cat found in a hollow tree on a BMS fungal foray in Windsor Great Park. The fur is heavily colonized with a keratinophilic *Arthroderma* sp. Courtesy of Dr Peter Austwick.

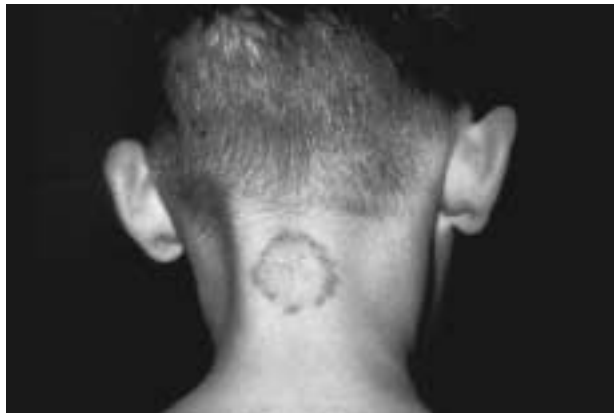

Fig 2 Typical ringworm lesion caused by *Trichophyton tonsurans*.

classical taxonomy.

Athlete's foot or *tinea pedis* the most widely suffered dermatophyte infection is considered a disease of affluence and a high standard of living. Most frequently caused by *Trichophyton rubrum*, it is common in countries where the majority of the population wears footwear and has ready access to communal sports or bathing facilities. Such conditions provide the ideal means of spread of shed infected skin squames which can remain contagious for prolonged periods in the environment. The warm, occlusive atmosphere afforded by footwear allows dormant fungal propagules to invade the moist, softened tissue of the interdigital spaces.

In contrast, scalp ringworm or *tinea capitis* was often seen as a sign of poor hygiene and a lower standard of living. From the early to the mid 1900's the most prevalent cause of scalp ringworm was the anthropophilic dermatophyte *Microsporum audouinii* Gruby which is highly infectious, this led to ostracization with the formation of special schools to segregate infected children. Even as late as the middle of the last century it was "considered by middle and upper class mothers to be a somewhat disreputable disease" (Ainsworth, 1952). The introduction of effective oral therapy led to a drastic reduction. Today in the UK scalp ringworm (Fig 2) is more frequently caused by another anthropophilic species *Trichophyton tonsurans* Molsten prevalent in the Afro-Caribbean population and also *Microsporum canis* Bodin acquired from cats and dogs. The incidence of *tinea capitis* due to *Trichophyton tonsurans* has increased more than 16 fold in the last 10 years in the UK and a carrier state has been recognized in which an undetected index case may be responsible for direct or indirect transmission of infection to others. Infections such as *tinea cruris* (groin infection commonly known as 'jock itch') and *tinea corporis* (body) are more often seen in adolescents or adults and are usually due to direct person to person or less

commonly animal or soil to person spread.

The term '*tinea*' to denote ringworm infections arose from the observation that the lesions caused by dermatophyte fungi resemble the holes eaten in fabric by larvae of the clothes moth *Tineola biselliella* and has been in use since the fourteenth century. The anglicized 'rynge-worme' appears to date from the fifteenth century and was probably coined because dermatophyte lesions of smooth skin often heal in the centre as the fungus spreads out from a central inoculum point. This results in a circular lesion or ring with a raised, inflamed, flaky and red periphery and a clear centre (see Fig 1).

Dr Sabouraud was one of the first to formally categorize this group of organisms and produced a remarkable tome in 1910 (*Les Teignes*, Libraires de l'Academie de Medicine) which describes culture of the dermatophytes in detail along with extensive photogravure plates, drawings, clinical descriptions and discussion of treatment. Although the taxonomic classification has been modified since this time this rightly earned him a central position in twentieth century medical mycology and a lasting impact in the form of Sabouraud's Agar. This peptone-sugar medium developed by Sabouraud in the late 19th century was revolutionary in enabling fungi to be grown, studied and described under standardized conditions an important advance given the way in which most macroscopic and microscopic features are influenced by the nutritional value of the growth substrate.

Although not part of the normal skin flora, dermatophytes have the ability to utilize keratin as a nutrient source and are thus well adapted to a role in cutaneous infection. It is interesting that Dermatophytes rarely if ever infect tissue below the cornified layers. It can be argued in fact that they really only colonize dead layers and are therefore not true pathogens. However their ability to cause inflammation, itching and acute discomfort is something that many people will give testament to! Initiation of infection relies on adherence of arthroconidia followed by rapid germination and hyphal penetration before epidermal cell proliferation results in desquamation of the infected cells. Dermatophytes produce a variety of proteinases including keratinases to facilitate rapid penetration of the stratum corneum. Growth in the skin is as branching septate mycelium sometimes with the formation of arthrospores resulting from the fragmentation of hyphae. Diagnosis is made by microscopic observation of fungal mycelium in skin scales, hair (Fig 3) or nail specimens softened in 20% caustic potash (KOH) and squashed to produce a monolayer but this does not allow identification of the

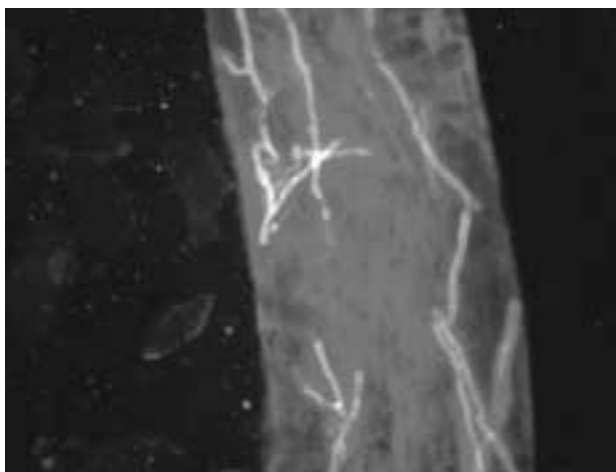


Fig 3 Calcofluor staining of mycelium of *Trichophyton tonsurans* in an infected hair.

infecting species. Keratinized skin is a relatively poor nutritional medium and this may be one reason why the characteristic microconidia and macroconidia of dermatophytes are not formed *in vivo*. Thus in order to identify the infecting organism skin, nail or hair samples have to be cultured on a rich medium in order to encourage spore formation. The resulting production of spores in the laboratory may be the first time that the organism has utilized this reproductive mechanism for many generations or hundreds of thousands of years.

The observation that dermatophyte infections occur significantly more commonly in males than females and that scalp ringworm is much less common after puberty has led to the discovery of steroid-mediated inhibition of growth. Infection with dermatophyte fungi elicits a cell-mediated immune response directed primarily against the antigen trichophytin. This inflammatory response is particularly marked following human infection with zoophilic organisms reflecting their relative lack of adaptation to parasitic life on a human host. Factors that can predispose to chronic dermatophyte infection include collagen vascular disease, corticosteroid administration, diabetes mellitus, haematological malignancy, atopy and old age. An inherited tendency to develop chronic infection linked to an autosomal recessive trait has also been documented.

Treatment of dermatophyte infections has had a somewhat chequered course. Early barbaric treatment of scalp ringworm included tar cap or pitch plaster epilation in which the hair was imbedded in a sticky cap which was allowed to set and then torn from the head to remove

the hair at the roots. A treatment that was considered far less barbaric but in truth was potentially much more damaging was introduced in the early 20th century by Sabouraud following the observation that doses of radiation caused hair loss. A rather sinister-looking apparatus was constructed and used to administer doses of radiation to targeted areas of the scalp.

The first oral agent for dermatophyte infection followed the discovery by Professor Jimmy Gentles in 1958 that griseofulvin, an antibiotic produced by the mould *Penicillium griseofulvum*, had anti-dermatophyte activity. This remained the mainstay of oral therapy for many years until the introduction of azole antifungals and the allylamine terbinafine and still retains a place in the treatment of scalp infections. There is a plethora of effective over-the-counter remedies for the topical treatment of localized skin infections ranging from zinc-based Whitfield's ointment to a large number of imidazole creams. The total market for compounds, antibiotics and ointments that treat dermatophytes is as large or greater than that used to treat all life threatening fungal infections. Notable in recent years has been a sharp rise in the number of individuals seeking treatment for onychomycosis (nail infection) due to dermatophytes. Whether this indicates a true increasing incidence or is merely a reflection of the perception that this is now a readily treatable condition thus encouraging infected individuals to seek therapy is not clear. Despite the introduction of newer fungicidal agents such as terbinafine treatment of fungal nail infection is still an uncertain and lengthy procedure with treatment regimens of up to six months for toenails.

Recent developments in the molecular analysis of dermatophyte fungi has led to some interesting epidemiological observations and will help to further elucidate the relationships and population dynamics of this group of human parasites.

References

- Ainsworth G. C. 1952. *Medical Mycology: An Introduction to its Problems*. Sir Isaac Pitman & Sons Ltd, London
- Padhye, A.A. & Weitzman, I. 1998. *The Dermatophytes*. In Topley and Wilson's Microbiology and Microbial Infections 9th Edition Vol 4 (Eds. L. Ajello and R.J. Hay) Edward Arnold, London.
- Sabouraud R, 1910. *Les Teignes*, Libraires de l'Academie de Medicine, Masson, Paris